

# Cancer of the cervix uteri

Neerja Bhatla<sup>1,\*</sup> | Daisuke Aoki<sup>2</sup> | Daya Nand Sharma<sup>3</sup> | Rengaswamy Sankaranarayanan<sup>4</sup>

<sup>1</sup>Department of Obstetrics and Gynecology, All India Institute of Medical Sciences, New Delhi, India

<sup>2</sup>Department of Obstetrics and Gynecology, Keio University School of Medicine, Tokyo, Japan

<sup>3</sup>Department of Radiation Oncology, All India Institute of Medical Sciences, New Delhi, India

<sup>4</sup>Early Detection and Prevention Group, International Agency for Research on Cancer, Lyon, France

## \*Correspondence

Neerja Bhatla, Department of Obstetrics and Gynecology, All India Institute of Medical Sciences, New Delhi, India.  
Email: nbhatla@aiims.ac.in

## Abstract

Since the publication of the last FIGO Cancer Report there have been giant strides in the global effort to reduce the burden of cervical cancer, with WHO announcing a call for elimination. In over 80 countries, including LMICs, HPV vaccination is now included in the national program. Screening has also seen major advances with implementation of HPV testing on a larger scale. However, these interventions will take a few years to show their impact. Meanwhile, over half a million new cases are added each year. Recent developments in imaging and increased use of minimally invasive surgery have changed the paradigm for management of these cases. The FIGO Gynecologic Oncology Committee has revised the staging system based on these advances. This chapter discusses the management of cervical cancer based on the stage of disease, including attention to palliation and quality of life issues.

## KEYWORDS

Cervix; FIGO Cancer Report; Gynecologic cancer; HPV vaccination; Radiation; Screening; Staging; Surgery

## 1 | INTRODUCTION

Globally, cervical cancer continues to be one of the most common cancers among females, being the fourth most common after breast, colorectal, and lung cancer. In 2012, it was estimated that there were approximately 527 600 new cases of cervical cancer with 265 700 deaths annually.<sup>1</sup> In low- and middle-income countries (LMICs), it is more common, being the second most common cancer in incidence among women and the third most common in terms of mortality. The majority of new cases and deaths (approximately 85% and 90%, respectively) occur in low-resource regions or among people from socioeconomically weaker sections of society.

## 2 | ANATOMICAL CONSIDERATIONS

The cervix, which is the lowermost part of the uterus, is a cylindrical-shaped structure composed of stroma and epithelium. The intravaginal part, the ectocervix, projects into the vagina and is lined by squamous epithelium. The endocervical canal extends from the internal os at

the junction with the uterus to the external os which opens into the vagina and is lined by columnar epithelium. Almost all cases of cervical carcinoma originate in the transformation zone from the ecto- or endocervical mucosa. The transformation zone is the area of the cervix between the old and new squamocolumnar junction.

The fact that the cervix can be easily visualized and sampled, and can be treated by freezing and burning with little or no anesthesia, has contributed to the understanding of the natural history of this cancer along with the development of simple outpatient techniques of screening and prevention.

## 3 | EARLY DETECTION AND PREVENTION OF CERVICAL CANCER

It is now recognized that cervical cancer is a rare long-term outcome of persistent infection of the lower genital tract by one of about 15 high-risk HPV types, which is termed the “necessary” cause of cervical cancer. Of the estimated 530 000 new cervical cancer cases annually, HPV 16 and HPV 18 account for 71%

This is an open access article under the terms of the Creative Commons Attribution License, which permits use, distribution and reproduction in any medium, provided the original work is properly cited.

© 2018 The Authors. *International Journal of Gynecology & Obstetrics* published by John Wiley & Sons Ltd on behalf of International Federation of Gynecology and Obstetrics

of cases; while HPV types 31, 33, 45, 52, and 58 account for another 19% of cervical cancer cases<sup>2,3</sup> It is well documented that nearly 90% of incident HPV infections are not detectable within a period of 2 years from the acquisition of infection and persist only in a small proportion. It is debatable whether the virus is completely cleared or whether it remains latent in basal cells with the potential for reactivation in some cases. Persistent HPV infection denotes the presence of the same type-specific HPV DNA on repeated sampling after 6–12 months. Only one-tenth of all infections become persistent, and these women could develop cervical precancerous lesions.

This knowledge has resulted in the development of new initiatives for prevention and early detection. The two major approaches for control of cervical cancer involve: (1) prevention of invasive cancer by HPV vaccination; and (2) screening for precancerous lesions. Prevention and elimination are potential possibilities but the tragedy is that it is not yet prevented on a large scale in many LMICs due to lack of efficient and effective intervention programs. WHO has recently given a call to action for elimination of cervical cancer. This is foreseeable if implemented in earnest in successful public health programs achieving high coverage.

### 3.1 | Primary prevention of cervical cancer with HPV vaccination

The fact that more than 80% of women followed over time will acquire at least one high-risk HPV infection suggests the ubiquitous nature of the HPV infection and reflects the ease of transmission. The estimated cross-sectional HPV prevalence worldwide among healthy women is around 11.7%, with the highest in Sub-Saharan Africa at around 24%, and country-specific prevalence ranging between 2% and 42% globally<sup>4</sup> Age-specific cross-sectional HPV prevalence peaks at 25% in women aged less than 25 years, which suggests that the infection is predominantly transmitted through the sexual route following sexual debut. Thus, prophylactic HPV vaccination as a preventive strategy should target women before initiation of sexual activity, focusing on girls aged 10–14 years.

Three prophylactic HPV vaccines are currently available in many countries for use in females and males from the age of 9 years for the prevention of premalignant lesions and cancers affecting the cervix, vulva, vagina, and anus caused by high-risk HPV types: a bivalent vaccine targeting HPV16 and HPV18; a quadrivalent vaccine targeting HPV6 and HPV11 in addition to HPV16 and HPV18; and a nonavalent vaccine targeting HPV types 31, 33, 45, 52, and 58 in addition to HPV 6, 11, 16, and 18. The last two vaccines target anogenital warts caused by HPV 6 and 11 in addition to the above-mentioned malignant and premalignant lesions. All the vaccines are recombinant vaccines composed of virus-like particles (VLPs) and are not infectious since they do not contain viral DNA. For girls and boys aged 9–14 years, a two-dose schedule (0.5 mL at 0 and 5–13 months) is recommended. If the second vaccine dose is administered earlier than 5 months after the first dose, a third dose is recommended. For those aged 15 years and above, and

for immunocompromised patients irrespective of age, the recommendation is for three doses (0.5 mL at 0, 1, 6 months).<sup>5</sup> WHO has reviewed the latest data and concluded that there is no safety concern regarding HPV vaccines.<sup>5</sup>

There is evidence for the effectiveness of vaccination at the population level in terms of reduced prevalence of high-risk HPV types, and reduction in anogenital warts and high-grade cervical abnormalities caused by the vaccine types among young women; there is some evidence of cross-protection from nonvaccine types also. There is no evidence of type replacement<sup>6–8</sup> Recent observational studies have reported evidence for effectiveness in preventing high-risk HPV infections following a single dose and further long-term follow-up will clarify the role of one dose in preventing cervical neoplasia.<sup>9,10</sup>

### 3.2 | Secondary prevention of cervical cancer by early detection and treatment of precancerous lesions

Even with the advent of effective vaccines, screening will remain a priority for cervical cancer prevention for several decades. Cervical cancer screening has been successful in preventing cancer by detection and treatment of precursor lesions, namely, high-grade cervical intraepithelial neoplasia (CIN 2 and 3) and adenocarcinoma in-situ (AIS).

Several cervical screening strategies have been found to be effective in varied settings. The tests used widely include conventional cytology (Pap smear), in recent years liquid-based cytology and HPV testing, and, in LMICs, visual inspection with acetic acid (VIA).<sup>11</sup> While the Pap smear is still the major workhorse of screening and is associated with substantial declines in cervical cancer risk in high-income countries, it is a challenging and resource intensive technology that is not feasible in low-resource settings<sup>11</sup> where poor organization, coverage, and lack of quality assurance result in sub-optimal outcomes. In the context of declining HPV infections after the introduction of HPV vaccines a decade ago, many healthcare systems are considering switching to primary HPV screening, which has higher sensitivity and negative predictive value, and allows extended screening intervals or even a single lifetime screening in low-resource settings.<sup>12,13</sup> VIA involves detection of acetowhite lesions on the cervix 1 minute after application of 3%–5% freshly prepared acetic acid. In view of its feasibility, VIA screening has been widely implemented in opportunistic settings in many low-income countries in Sub-Saharan Africa. A single-visit approach (SVA) for screening with rapid diagnosis and treatment improves coverage, eliminates follow-up visits, and makes screening more time and cost-efficient in low-resource settings.<sup>14–16</sup> VIA screening is particularly suitable for SVA and WHO has issued guidelines for implementing SVA in public health settings.

A single screening modality will never be universally applicable, but it is possible to adapt cost-effective means of cervical cancer screening to each country. The screening strategy chosen must be feasible, simple, safe, accurate, acceptable, and easily accessible to highest-risk women. A judicious combination of HPV vaccination and

screening has enormous potential to eliminate cervical cancer in the foreseeable future.

## 4 | FIGO STAGING

Cervical cancer spreads by direct extension into the parametrium, vagina, uterus and adjacent organs, i.e., bladder and rectum. It also spreads along the lymphatic channels to the regional lymph nodes, namely, obturator, external iliac and internal iliac, and thence to the common iliac and para-aortic nodes. Distant metastasis to lungs, liver, and skeleton by the hematogenous route is a late phenomenon.

Until now, the FIGO staging was based mainly on clinical examination with the addition of certain procedures that were allowed by FIGO to change the staging. In 2018, this has been revised by the FIGO Gynecologic Oncology Committee to allow imaging and pathological findings, where available, to assign the stage. The revised staging

is shown in Table 1 (presented at the FIGO XXII World Congress of Gynecology and Obstetrics<sup>17</sup>).

## 4.1 | Diagnosis and evaluation of cervical cancer

### 4.1.1 | Microinvasive disease

Diagnosis of Stage IA1 and IA2 is made on microscopic examination of a LEEP (loop electrosurgical excision procedure) or cone biopsy specimen, which includes the entire lesion. It can also be made on a trachelectomy or hysterectomy specimen. The depth of invasion should not be greater than 3 mm or 5 mm, respectively, from the base of the epithelium, either squamous or glandular, from which it originates. The horizontal dimension is no longer considered in the 2018 revision as it is subject to many artefactual errors. Note must be made of lymphovascular space involvement, which does not alter the stage, but may affect the treatment plan. Extension to the uterine corpus is

**TABLE 1** FIGO staging of cancer of the cervix uteri (2018).

Stage	Description
I	The carcinoma is strictly confined to the cervix (extension to the uterine corpus should be disregarded)
IA	Invasive carcinoma that can be diagnosed only by microscopy, with maximum depth of invasion <5 mm <sup>a</sup>
IA1	Measured stromal invasion <3 mm in depth
IA2	Measured stromal invasion ≥3 mm and <5 mm in depth
IB	Invasive carcinoma with measured deepest invasion ≥5 mm (greater than Stage IA), lesion limited to the cervix uteri <sup>b</sup>
IB1	Invasive carcinoma ≥5 mm depth of stromal invasion, and <2 cm in greatest dimension
IB2	Invasive carcinoma ≥2 cm and <4 cm in greatest dimension
IB3	Invasive carcinoma ≥4 cm in greatest dimension
II	The carcinoma invades beyond the uterus, but has not extended onto the lower third of the vagina or to the pelvic wall
IIA	Involvement limited to the upper two-thirds of the vagina without parametrial involvement
IIA1	Invasive carcinoma <4 cm in greatest dimension
IIA2	Invasive carcinoma ≥4 cm in greatest dimension
IIB	With parametrial involvement but not up to the pelvic wall
III	The carcinoma involves the lower third of the vagina and/or extends to the pelvic wall and/or causes hydronephrosis or nonfunctioning kidney and/or involves pelvic and/or para-aortic lymph nodes <sup>c</sup>
IIIA	The carcinoma involves the lower third of the vagina, with no extension to the pelvic wall
IIIB	Extension to the pelvic wall and/or hydronephrosis or nonfunctioning kidney (unless known to be due to another cause)
IIIC	Involvement of pelvic and/or para-aortic lymph nodes, irrespective of tumor size and extent (with r and p notations) <sup>c</sup>
IIIC1	Pelvic lymph node metastasis only
IIIC2	Para-aortic lymph node metastasis
IV	The carcinoma has extended beyond the true pelvis or has involved (biopsy proven) the mucosa of the bladder or rectum. (A bullous edema, as such, does not permit a case to be allotted to Stage IV)
IVA	Spread to adjacent pelvic organs
IVB	Spread to distant organs

When in doubt, the lower staging should be assigned.

<sup>a</sup>Imaging and pathology can be used, where available, to supplement clinical findings with respect to tumor size and extent, in all stages.

<sup>b</sup>The involvement of vascular/lymphatic spaces does not change the staging. The lateral extent of the lesion is no longer considered.

<sup>c</sup>Adding notation of r (imaging) and p (pathology) to indicate the findings that are used to allocate the case to Stage IIIC. Example: If imaging indicates pelvic lymph node metastasis, the stage allocation would be Stage IIIC1r, and if confirmed by pathologic findings, it would be Stage IIIC1p. The type of imaging modality or pathology technique used should always be documented.

Source: Bhatla et al.<sup>17</sup>

also disregarded for staging purposes as it does not in itself alter either the prognosis or management. The margins should be reported to be negative for disease. If the margins of the cone biopsy are positive for invasive cancer, the patient is allocated to Stage IB1.<sup>18</sup>

Clinically visible lesions, and those with larger dimensions, are allocated to Stage IB, subdivided in the latest staging as IB1, IB2, and IB3 based on the maximum diameter of the lesion.

#### 4.1.2 | Invasive disease

In the case of visible lesions, a punch biopsy may generally suffice, but if not satisfactory a small loop biopsy or cone may be required. Clinical assessment is the first step in allocation of staging.

Imaging evaluation may now be used in addition to clinical examination where resources permit. The revised staging permits the use of any of the imaging modalities according to available resources, i.e. ultrasound, CT, MRI, positron emission tomography (PET), to provide information on tumor size, nodal status, and local or systemic spread. The accuracy of various methods depends on the skill of the operator. MRI is the best method of radiologic assessment of primary tumors greater than 10 mm.<sup>19–23</sup> However, ultrasound has also been shown to have good diagnostic accuracy in expert hands.<sup>24</sup> The modality used in assigning staging should be noted for future evaluation. Imaging has the advantage of the ability to identify additional prognostic factors, which can guide the choice of treatment modality. The goal is to identify the most appropriate method and to avoid dual therapy with surgery and radiation as this has the potential to greatly augment morbidity.

For detection of nodal metastasis greater than 10 mm, PET-CT is more accurate than CT and MRI, with false-negative results in 4%–15% of cases.<sup>20,25–28</sup> In areas with a high prevalence of tuberculosis and inflammation, especially HIV-endemic areas, large lymph nodes are not necessarily metastatic. The clinician may make the decision on imaging or, when possible, can use fine needle aspiration or biopsy to establish or exclude metastases.<sup>27,29,30</sup> This is especially true in advanced stages, where surgical assessment of para-aortic lymph nodes may be used to tailor treatment according to extent of disease.<sup>31–33</sup> They can be accessed by minimally invasive surgery or laparotomy. Surgical exclusion of para-aortic lymph node involvement has been reported to have a better prognosis than radiographic exclusion alone.<sup>34</sup>

A review of 22 articles that assessed the safety and impact of pre-treatment para-aortic lymph node surgical staging (PALNS) found that 18% (range, 8%–42%) of patients with Stage IB–IVA cervical cancer had para-aortic lymph node metastases.<sup>35</sup> The mean complication rate of PALNS was 9% (range 4%–24%), with lymphocyst formation being the most common. In another study, up to 35% of clinically assessed Stage IIB and 20% of Stage III tumors were reported to have positive para-aortic nodes.<sup>36</sup> In the revised staging, all these cases will be assigned to Stage IIIC as lymph node involvement confers a worse prognosis.<sup>37</sup> If only pelvic nodes are positive, it is Stage IIIC1; if para-aortic nodes are also involved it is Stage IIIC2. A further notation must be added to indicate whether this allocation is based on only imaging assessment (r) or whether pathological confirmation is available (p). In due course, the data can be analyzed and reported accordingly.

FIGO no longer mandates any biochemical investigations or investigative procedures; however, in patients with frank invasive carcinoma, a chest X-ray, and assessment of hydronephrosis (with renal ultrasound, intravenous pyelography, CT, or MRI) should be done. The bladder and rectum are evaluated by cystoscopy and sigmoidoscopy only if the patient is clinically symptomatic. Cystoscopy is also recommended in cases of a barrel-shaped endocervical growth and in cases where the growth has extended to the anterior vaginal wall. Suspected bladder or rectal involvement should be confirmed by biopsy and histologic evidence. Bullous edema alone does not warrant a case to be allocated to Stage IV.

#### 4.2 | Pathologic staging

In case a surgical specimen is available or where image-guided fine-needle aspiration cytology has been done, the pathologic report is an important source for accurate assessment of the extent of disease. As in the case of imaging, the pathologic methods should also be recorded for future evaluation. The stage is to be allocated after all imaging and pathology reports are available. It cannot be altered later, for example at recurrence. The 2018 FIGO staging includes involvement of nodes and thus enables both the selection and evaluation of therapy, as well as estimation of the prognosis and calculation of end results.

The FIGO and TNM classifications have been virtually identical in describing the anatomical extent of disease. The TNM nomenclature has hitherto been used for the purpose of documenting nodal and metastatic disease status.<sup>38</sup> The revised FIGO classification is now more closely aligned with the TNM classification in this respect as well.

In some cases, hysterectomy is performed in the presence of unsuspected invasive cervical carcinoma that is diagnosed later on histopathology. Such cases cannot be clinically staged or included in therapeutic statistics for obvious reasons, but reporting them separately is desirable.

#### 4.3 | Histopathology

It is essential that all cancers must be confirmed by microscopic examination. Cases are classified as carcinomas of the cervix if the primary growth is in the cervix. All histologic types must be included. The histopathologic types, as described in the World Health Organization's 2014 Tumours of the Female Reproductive Organs<sup>39</sup> are:

1. Squamous cell carcinoma (keratinizing; non-keratinizing; papillary, basaloid, warty, verrucous, squamotransitional, lymphoepithelioma-like)
2. Adenocarcinoma (endocervical; mucinous, villoglandular, endometrioid)
3. Clear cell adenocarcinoma
4. Serous carcinoma
5. Adenosquamous carcinoma
6. Glassy cell carcinoma
7. Adenoid cystic carcinoma
8. Adenoid basal carcinoma
9. Small cell carcinoma
10. Undifferentiated carcinoma

Grading by any of several methods is encouraged, but it is not a basis for modifying the stage groupings in cervical carcinoma. Histopathologic grades are as follows:

1. GX: Grade cannot be assessed
2. G1: Well differentiated
3. G2: Moderately differentiated
4. G3: Poorly or undifferentiated

## 5 | MANAGEMENT OF CERVICAL CANCER

Management of cervical cancer is primarily by surgery or radiation therapy, with chemotherapy a valuable adjunct.

### 5.1 | Surgical management

Surgery is suitable for early stages, where cervical conization, total simple hysterectomy, or radical hysterectomy may be selected according to the stage of disease and extent of spread of cervical cancer. Table 2 shows the types of radical hysterectomy. In Stage IVA, there is a place for pelvic exenteration in selected cases.

#### 5.1.1 | Microinvasive cervical carcinoma: FIGO Stage IA

##### 5.1.1.1 | Stage IA1

The treatment is completed with cervical conization unless there is lymphovascular space invasion (LVSI) or tumor cells are present at the surgical margin. In women who have completed childbearing or elderly women, total extrafascial hysterectomy may also

be recommended.<sup>40</sup> Any route can be chosen, i.e. abdominal, vaginal, or laparoscopic. When LVSI is evident, pelvic lymphadenectomy should be considered, along with modified radical hysterectomy.<sup>41,42</sup> If fertility is desired, cervical conization with close follow-up will be adequate.

##### 5.1.1.2 | Stage IA2

Since there is a small risk of lymph node metastases in these cases,<sup>42–45</sup> pelvic lymphadenectomy is performed in addition to type B radical hysterectomy or more radical surgery.<sup>46,47</sup> In low risk cases, simple hysterectomy or trachelectomy, with either pelvic lymphadenectomy or sentinel lymph node assessment, may be adequate surgical treatment.<sup>48,49</sup> When the patient desires fertility, she may be offered a choice of the following: (1) cervical conization with laparoscopic (or extraperitoneal) pelvic lymphadenectomy; or (2) radical abdominal, vaginal, or laparoscopic trachelectomy with pelvic lymphadenectomy.<sup>50,51</sup>

##### 5.1.1.3 | Post-treatment follow-up

Follow-up with 3-monthly Pap smears for 2 years, then 6-monthly for the next 3 years is recommended after treatment of microinvasive carcinoma. With normal follow-up at 5 years, the patient can return to the routine screening schedule according to the national guidelines.<sup>40</sup>

#### 5.1.2 | Invasive cervical carcinoma: FIGO Stage IB1, IB2, IIA1

Surgical treatment is the preferred modality for the treatment of Stage IB1, IB2, and IIA1 lesions. It would usually consist of type C radical hysterectomy with pelvic lymphadenectomy.<sup>52–54</sup> The routes of surgery may be open or minimally invasive, i.e. laparoscopic or robotic.

**TABLE 2** Types of radical hysterectomy.

	Simple extrafascial hysterectomy	Modified radical hysterectomy	Radical hysterectomy
Piver and Rutledge Classification	Type I	Type II	Type III
Querleu and Morrow classification	Type A	Type B	Type C
Indication	Stage IA1	Type IA1 with LVSI. IA2	Stage IB1 and IB2, selected Stage IIA
Uterus and cervix	Removed	Removed	Removed
Ovaries	Optional removal	Optional removal	Optional removal
Vaginal margin	None	1–2 cm	Upper one-quarter to one-third
Ureters	Not mobilized	Tunnel through broad ligament	Tunnel through broad ligament
Cardinal ligaments	Divided at uterine and cervical border	Divided where ureter transits broad ligaments	Divided at pelvic side wall
Uterosacral ligaments	Divided at cervical border	Partially removed	Divided near sacral origin
Urinary bladder	Mobilized to base of bladder	Mobilized to upper vagina	Mobilized to middle vagina
Rectum	Not mobilized	Mobilized below cervix	Mobilized below cervix
Surgical approach	Laparotomy or laparoscopy or robotic surgery	Laparotomy or laparoscopy or robotic surgery	Laparotomy or laparoscopy or robotic surgery

### 5.1.2.1 | FIGO Stage IB1

FIGO Stage IB1 is considered as low risk with the following criteria: largest tumor diameter less than 2 cm, cervical stromal invasion less than 50%, and no suspicious lymph nodes on imaging. The standard management is a type C radical hysterectomy, but modified radical hysterectomy may be considered in these cases. Pelvic lymphadenectomy should always be included on account of the high frequency of lymph node involvement.<sup>46,47</sup>

A pelvic nerve-sparing surgical procedure is recommended in patients undergoing radical hysterectomy, in so far as radical curability is maintained, as intrapelvic injuries to the autonomic nerves (i.e. hypogastric nerve, splanchnic nerve, and pelvic plexus) often lead to impairment of urination, defecation, and sexual function, and consequent deterioration of the postoperative quality of life (QOL).<sup>55,56</sup>

In young women desiring fertility sparing, a radical trachelectomy may be performed, indicated for Stage IA2–IB1 tumors measuring less than or equal to 2 cm in largest diameter.<sup>57</sup> The cervix along with the parametrium is removed followed by anastomosis of the uterus with the vaginal end. Trachelectomy can be done by open abdominal, vaginal, or by minimally invasive routes. When a vaginal approach is planned, the pelvic nodes are first removed laparoscopically and sent for frozen section to confirm node negativity and then proceed with the radical trachelectomy vaginally. Alternatively, the nodes may be first be assessed by conventional pathologic methods and the radical trachelectomy done as a second surgery after 1 week.

### 5.1.2.2 | FIGO Stage IB2 and IIA1

In FIGO Stage IB2 and IIA1 cervical cancer, surgery or radiotherapy can be chosen as the primary treatment depending on other patient factors and local resources, as both have similar outcomes. The advantages of surgical treatment are: (1) that it is feasible to determine the postoperative stage precisely on the basis of histopathologic findings, thereby enabling individualization of postoperative treatment for each patient; (2) that it is possible to treat cancers that are likely to be resistant to radiotherapy; and (3) that it is possible to conserve ovarian function. Intraoperative transpositioning of the ovaries high in the paracolic gutters away from the radiation field, in case it should be required subsequently, is also feasible. The preservation of ovarian and sexual function makes surgery the preferred mode in younger women. Type C radical hysterectomy represents a basic procedure for the treatment of cervical cancer, consisting of removal of the uterus, parametrium, upper vagina, and a part of the paracolpium, along with pelvic lymphadenectomy. As for the adjacent connective tissues, the anterior vesicouterine ligament (anterior and posterior leaf), lateral cardinal ligaments, and posterior sacrouterine and rectovaginal ligaments are cut from the uterus at sufficient distances from their attachments to the uterus. Lymphadenectomy constitutes one of the bases of this surgical procedure, and the extent of regional lymph node excision includes the parametrial nodes, obturator nodes, external, internal, and common iliac nodes.

The role of sentinel lymph node (SLN) mapping in cervical cancer is still experimental and needs more evidence to include into routine

practice. It may have some role in early stage cervical cancer, i.e. FIGO Stage IA, IB1, and IB2.<sup>58–60</sup> Dual labeling using blue dye and radiocolloid increases the accuracy of sentinel lymph nodes can be performed with.<sup>61,62</sup> Indocyanine green dye with near infrared technique has been used in robotic surgery and laparoscopy. Pelvic lymphadenectomy needs to be considered if LVSI is present.

The route of surgery may be laparotomy or minimally invasive surgery, either laparoscopic or robotic. The LACC trial (Laparoscopic Approach to Cervical Cancer) compared the overall survival with open surgery versus laparoscopy or robotic surgery in early stage cervical cancer and showed a decreased overall survival (3 of 312 vs 19 of 319, HR 6.00, 95% CI, 1.48–20.3,  $P=0.004$ ). Disease-free survival events showed a three-fold increase in the minimally invasive surgery group (7 of 312 vs 27 of 319, HR 3.74, 95% CI, 1.63–8.58;  $P=0.002$ ). Rates of intraoperative complications did not differ by treatment received (11% in both). They concluded that hysterectomy by a minimally invasive route was associated with higher rates of recurrence than the open approach in early-stage cervical cancer patients.<sup>63</sup> Further studies may be required to further confirm these findings.

### 5.1.3 | FIGO Stage IB3 and IIA2

In Stage IB3 and IIA2, the tumors are larger and the likelihood of high risk factors such as positive lymph nodes, positive parametria, or positive surgical margins that increase the risk of recurrence and require adjuvant radiation after surgery are high. Other risk factors that increase the risk of pelvic recurrence even when nodes are not involved include: largest tumor diameter greater than 4 cm, LVSI, and invasion of outer one-third of the cervical stroma.<sup>64,65</sup> In such cases, adjuvant whole pelvic irradiation reduces the local failure rate and improves progression-free survival compared with patients treated with surgery alone.<sup>65</sup> However, the dual modality treatment increases the risk of major morbidity to the patient.

The treatment modality must, therefore, be determined based on the availability of resources and tumor- and patient-related factors. Concurrent platinum-based chemoradiation (CCRT) is the preferred treatment option for Stage IB3 to IIA2 lesions. It has been demonstrated that the prognosis is more favorable with CCRT, rather than radiotherapy alone, as postoperative adjuvant therapy as well in terms of overall survival, progression-free survival, and local and distant recurrences.<sup>52,66,67</sup>

In areas where radiotherapy facilities are scarce, neoadjuvant chemotherapy (NACT) has been used with the goal of: (1) down-staging of the tumor to improve the radical curability and safety of surgery; and (2) inhibition of micrometastasis and distant metastasis. There is no unanimity of view as to whether it improves prognosis compared with the standard treatment.<sup>68,69</sup>

The extent of surgery after NACT remains the same, i.e. radical hysterectomy and pelvic lymphadenectomy. The greater difficulty is in determining the indications for adjuvant therapy which are often kept the same as those after primary surgery.<sup>66,67</sup> However, it must be remembered that NACT may give a false sense of security by masking the pathologic findings and thus affecting evaluation of indications



for adjuvant radiotherapy/CCRT. NACT surgery is best reserved for research settings or those areas where radiotherapy is unavailable. This is especially true in patients with very large tumors or adenocarcinoma, which have lower response rates.<sup>70</sup>

### 5.1.4 | FIGO Stage IVA or recurrence

Rarely, patients with Stage IVA disease may have only central disease without involvement to the pelvic sidewall or distant spread. Such cases, or in case of such a recurrence, pelvic exenteration can be considered but usually has a poor prognosis.<sup>71–75</sup>

## 5.2 | Radiation management

In LMICs, the majority of patients present with locally advanced disease,<sup>76</sup> where surgery plays a limited role, and radiotherapy has an important role. Over the last two decades, development of sophisticated planning and delivery techniques, and introduction of computer technology and imaging have galvanized the practice of radiotherapy, resulting in improved clinical outcome and reduced toxicity.<sup>77,78</sup>

Apart from its curative role, radiotherapy can also be used as adjuvant therapy for operated patients to prevent locoregional recurrence, although the role of “dual modality” is discouraged, and as palliative therapy for alleviating distressing symptoms in patients with advanced incurable disease.

### 5.2.1 | Radiation therapy for early stage disease (FIGO Stage IA, IB1, IB2, and IIA1)

Although surgery is preferred for early stage disease, in cases with contraindications for surgery or anesthesia, radiotherapy provides equally good results in terms of local control and survival. Treatment decision should be made on the basis of clinical, anatomic, and social factors. Patients with microinvasive disease have been treated by intracavitary radiation therapy (ICRT) alone with good results if surgery is contraindicated owing to medical problems. Selected patients with very small Stage IB1 disease (less than 1 cm) may also be treated with ICRT alone, particularly if there are relative contraindications to external beam radiation therapy (EBRT).<sup>79</sup> A dose of 60–65 Gy equivalent is usually prescribed to Point A. Combination of EBRT and ICRT is also an option for such patients.

Both surgery and radiotherapy remain viable options for early stage disease. Definitive radiotherapy or concurrent chemoradiation (CCRT) is preferred in patients likely to require postoperative radiotherapy to avoid compounding treatment-related morbidity. There is a single randomized trial comparing surgery and radiotherapy<sup>52</sup> but none comparing surgery to CCRT, which is the current standard in patients treated by definitive radiotherapy. Landoni et al.<sup>52</sup> randomized patients with IB or IIA cervical cancer to surgery with or without postoperative radiotherapy (PORT) versus definitive radiotherapy alone. PORT was administered to 64% of patients in the surgery arm. The two treatment arms resulted in similar overall survival (83%) and disease-free survival (74%); severe morbidity was higher in the surgery

arm (28% vs 12%), likely due to contributions from both treatment modalities. An update of the same trial with 20-year follow-up data has shown marginally better results with radiotherapy compared with surgery (77% vs 72%,  $P=0.280$ ).<sup>80</sup> Multivariate analysis confirmed that risk factors for survival are histopathologic type ( $P=0.020$ ), tumor diameter ( $P=0.008$ ), and lymph node status ( $P<0.001$ ).<sup>80</sup>

### 5.2.2 | Adjuvant radiotherapy

Following radical hysterectomy, PORT with or without chemotherapy is indicated for patients with adverse pathologic factors such as positive pelvic nodes, parametrial infiltration, positive margins, deep stromal invasion, etc. According to various prognostic factors, patients may be categorized into high-risk, intermediate-risk, or low-risk disease. High-risk disease includes patients with either positive surgical margins or lymph node metastases or parametrial spread, and such patients should be offered PORT with chemotherapy since the GOG 109 trial has shown overall survival advantage.<sup>67</sup> Intermediate-risk patients with any two of three factors (tumor size more than 4 cm, lymphovascular invasion, deep stromal invasion) require PORT<sup>64,81</sup> and no chemotherapy should be offered to these patients. All other patients following radical hysterectomy are termed as low-risk disease patients and do not need any adjuvant therapy.

Tumor size of more than 4 cm is a well-known risk factor. Since 2009 it was incorporated in the FIGO staging system as Stage IB2 and now in the 2018 staging revision as Stage IB3. Recent literature, especially with the advent of more and more fertility sparing surgery suggests tumor size more than 2 cm is a risk factor.<sup>82–91</sup> In a recent study, Gerner et al.<sup>91</sup> evaluated various clinical and pathologic risk factors that may reduce the rate of multimodality treatment of early cervical cancer. The authors observed that 89% of patients with tumors 2 cm or greater and LVSI received radiotherapy and 76% of patients with tumors 2 cm or greater and depth of invasion greater than 10 mm received radiotherapy. They suggest that in patients with early cervical cancer, evaluation of tumor size and LVSI should be undertaken before performing radical hysterectomy to tailor treatment and to reduce the rate of employing both radical hysterectomy and chemoradiation. In view of the above-mentioned emerging literature, tumor size of more than 2 cm has been taken as the first cut-off in the 2018 revision of the FIGO staging system.

PORT consists of whole pelvic EBRT to cover the tumor bed and draining lymph node areas. A dose of 45–50 Gy is usually prescribed. Intensity modulated radiation therapy (IMRT), an advanced and refined technique of irradiation, has been explored in the postoperative setting to reduce the toxicity.<sup>92,93</sup> A recent Phase III trial<sup>93</sup> revealed improved patient reported outcomes at week five with IMRT, with no difference after treatment completion. Therefore, postoperative pelvic IMRT remains investigational until further data are published.

The role of vaginal brachytherapy boost following EBRT is not clear; however, it may be considered for patients with close or positive margins, large or deeply invasive tumors, parametrial or vaginal involvement, or extensive LVSI.<sup>94</sup> Vaginal cuff brachytherapy is usually delivered by ovoids or cylinders to the upper one-third of the residual

vagina and should include two weekly fractions of high dose rate (HDR) brachytherapy of 6 Gy each prescribed to 5 mm from the vaginal cylinder/ovoid surface.

### 5.2.3 | Radiation therapy for FIGO Stage IB3 and IIA2

Although feasible, surgery as initial treatment is not encouraged for patients with Stage IB3 and IIA2 disease since 80% of them require PORT or CCRT.<sup>52</sup> It is well known that the addition of adjuvant radiotherapy to surgery increases morbidity and thus compromises the quality of life.<sup>95,96</sup> Additionally, combined modality treatment will unnecessarily overburden the surgical and radiation facilities, which are already inadequate in low-resource countries. Therefore, CCRT is the standard of care for Stage IB3 and IIA2 disease. CCRT includes external radiation and intracavitary brachytherapy.<sup>65,66</sup>

### 5.2.4 | Radiation therapy for FIGO Stage IIB–IVA

Concurrent chemoradiation is considered the standard treatment for patients with locally advanced cervical cancer (LACC). The chemotherapy regimen is intravenous administration of weekly cisplatin during the course of EBRT.

Based on the results of five large randomized trials<sup>67,97–100</sup> that tested addition of chemotherapy to pelvic radiation, the National Cancer Centre issued an alert in 1999 that all patients with locally advanced cervical cancer should receive CCRT.<sup>67</sup> These studies<sup>67,97–100</sup> demonstrated that CCRT had a significant survival advantage of 10%–15% at 5 years after treatment compared with radiotherapy alone. A subsequent meta-analysis showed maximum benefit of chemoradiation of 6% in Stage IB2 (now termed IB3) to Stage IIB and only 3% benefit in Stage IIIB patients.<sup>101</sup> Concurrent chemoradiotherapy also reduced local and distant recurrence, and improved disease-free survival.

A once-weekly infusion of cisplatin (40 mg/m<sup>2</sup> weekly with appropriate hydration) for 5–6 cycles during external beam therapy is a commonly used concurrent chemotherapy regimen.<sup>99,102</sup> For patients who are unable to receive platinum chemotherapy, 5-fluorouracil-based regimens are an acceptable alternative.<sup>102–104</sup> Data on the toxicity associated with concurrent chemotherapy and extended field irradiation are limited.<sup>105,106</sup>

Additional adjuvant chemotherapy after concurrent chemoradiotherapy is being explored in an international randomized controlled trial (OUTBACK Trial).<sup>107</sup>

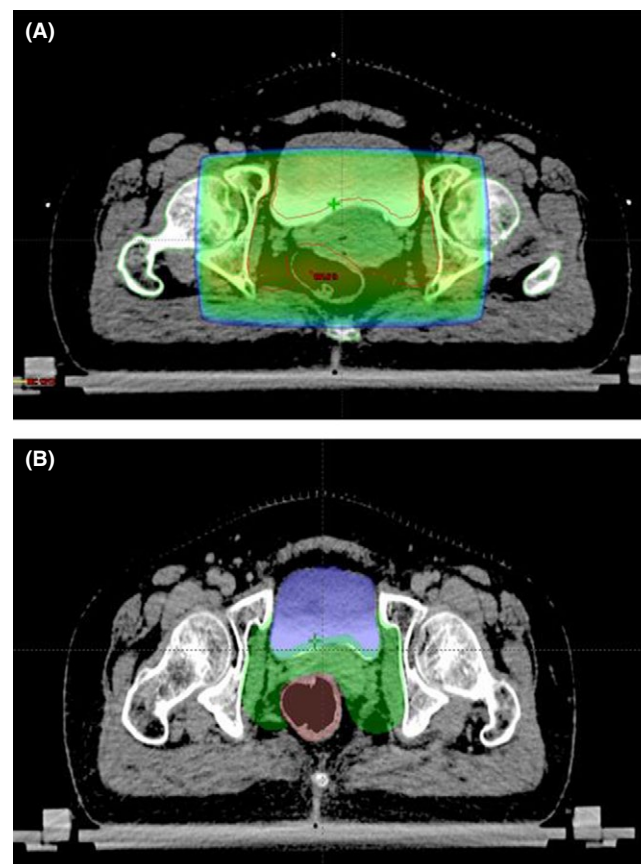
The combination of EBRT and ICRT maximizes the likelihood of locoregional control while minimizing the risk of treatment complications. The primary goal of EBRT is to sterilize local disease and to shrink the tumor to facilitate subsequent ICRT. Standard EBRT should deliver a dose of 45–50 Gy to the whole pelvis by 2 or 4 field box technique (Table 3) encompassing uterus, cervix, adnexal structures, parametria, and pelvic lymph nodes. Although EBRT is commonly delivered by a Cobalt-60 teletherapy machine in several low-resource countries, linear accelerators are preferred nowadays as they provide

**TABLE 3** Field design for the pelvic radiotherapy.

Field	Border	Landmark
AP-PA fields	Superior	L4–5 vertebral interspace
	Inferior	2 cm below the obturator foramen or 3 cm inferior to distal disease, whichever is lower
	Lateral	1.5–2 cm lateral to the pelvic brim
Lateral fields	Superior	Same as AP-PA field
	Inferior	Same as AP-PA field
	Anterior	Anterior to the pubic symphysis
	Posterior	0.5 cm posterior to the anterior border of the S2/3 vertebral junction. May include the entire sacrum to cover the disease extent

higher energy beams resulting in more homogeneous dose delivery to deep tissues with relative sparing of superficial tissues. Recently, conformal radiotherapy techniques like 3D-CRT and IMRT are increasingly being used with encouraging results in terms of reduced toxicity owing to relative sparing of normal tissues (Fig. 1).

Although EBRT plays an important role in the treatment of cervical cancer, ICRT is also an extremely important component of curative treatment of cervical cancer since it delivers a high central dose to the



**FIGURE 1** CT scan images showing radiotherapy planning using: (A) conventional four-field box technique; and (B) intensity modulated radiation therapy (IMRT) planning. Normal tissues such as bladder and bowel are relatively spared in IMRT planning.



primary tumor and reduced doses to adjacent normal organs owing to sharp dose fall-off.

Standard ICRT is usually performed using a tandem and two ovoids, or a tandem and ring. Any of the dose rate systems, namely low-dose-rate (LDR), high-dose-rate (HDR), or pulsed-dose-rate (PDR) may be practiced as all three yield comparable survival rates.<sup>108</sup> The dose is usually prescribed to Point A or to high-risk clinical target volume (HRCTV) if image-based planning is used.

With an LDR system, a dose of 30–40 Gy is prescribed in one or two sessions. With HDR, various dose fraction schedules are used, employing a dose of 5.5–8 Gy by 3–5 weekly fractions. Owing to resource constraints and long travelling distances in low-resource countries, delivering three instead of five fractions is often more realistic and allows for treatment of a higher number of patients. The total combined dose with EBRT and ICRT should be in the range of 80–90 Gy. Though PDR is rarely used, the overall treatment time and dose in PDR remains almost the same as in LDR except that the treatment is given in multiple hourly pulses each lasting for a few minutes.

If ICRT is not feasible either due to distorted anatomy or inadequate dosimetry, then interstitial brachytherapy should be considered. Interstitial brachytherapy consists of insertion of multiple needles/catheters into the primary tumor and parametria (Fig. 2) through the perineum with the help of a template. Due to the risk of trauma to normal structures like bowel and bladder, use of ultrasound imaging (especially transrectal) is suggested during the implant procedure.<sup>109</sup>

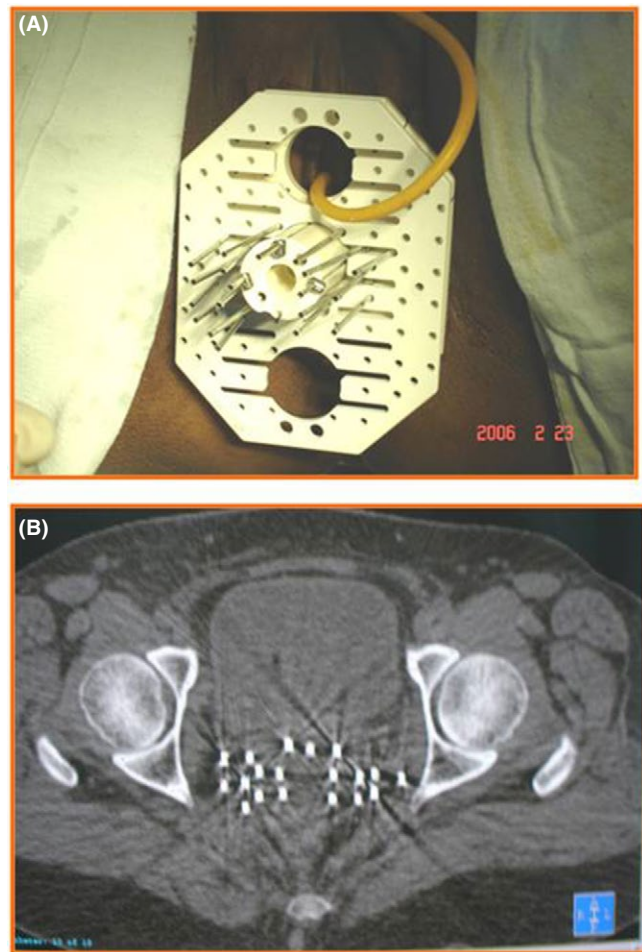
Completion of the radiotherapy protocol within the stipulated time is an important goal as it has a direct correlation on the outcome. In retrospective analyses, patients whose radiotherapy treatment times exceeded 9–10 weeks had significantly higher rates of pelvic failure when compared with women whose treatment was completed in less than 6–7 weeks.<sup>110,111</sup> Currently the recommendation is to complete the entire protocol of EBRT and brachytherapy within 8 weeks.

### 5.2.5 | FIGO Stage IVB/distant metastases

Presentation with distant metastatic disease is rare, reported in about 2% of cases. A management plan should consider that the median duration of survival with distant metastatic disease is approximately 7 months.

Concurrent chemoradiation may have better response than systemic chemotherapy with overall and disease-free survivals of 69% and 57%, respectively, reported in patients with positive para-aortic and supraclavicular lymph nodes.<sup>112</sup> Currently there is no role for prophylactic extended field radiotherapy (EFRT) in locally advanced cervical cancer. When para-aortic nodes are involved, EFRT with concurrent chemotherapy should be used. IMRT may be used in such patients to reduce the toxicity.

Despite limited response rates, cisplatin has been the standard chemotherapy used in the setting of distant metastatic disease.<sup>113</sup> Given low response rates to cisplatin alone after concurrent chemoradiation, recent evidence supports the use of platinum doublets over cisplatin alone, although with very modest benefits in response rates. Cisplatin may be combined with taxanes, topotecan, 5-fluorouracil, gemcitabine, or vinorelbine.<sup>114</sup> Carboplatin-paclitaxel combination has also been successful in these cases.



**FIGURE 2** Interstitial brachytherapy implant: (A) clinical image of a patient showing the perineal template and the steel needles; (B) CT scan image showing the brachytherapy needles inserted into the pelvis.

Patients with an ECOG (Eastern Cooperative Oncology Group) performance status of 0–2 may be considered for palliative systemic chemotherapy. Where feasible, these patients could be offered participation in clinical trials, especially when the interval to relapse is less than 12 months.

GOG 240 studied the efficacy of antiangiogenic therapy with bevacizumab, a humanized anti-VEGF monoclonal antibody. When incorporated in the treatment of recurrent and metastatic cervical cancer, it showed increased overall survival (17.0 months vs 13.3 months, HR for death 0.71, 98% CI 0.54–0.95,  $P=0.004$  in a one-sided test).<sup>115</sup> The treatment is presently expensive and patients and their families need to be counseled. Adverse effects include increased incidence of hypertension, thromboembolic events, and gastrointestinal fistulae.

### 5.2.6 | Radiation therapy after inadvertent incomplete surgery

Invasive cervical cancer may be found during pathologic evaluation of the specimen of a simple hysterectomy for an apparent benign condition. Inadvertent simple hysterectomy is considered inadequate

surgery for invasive cervical carcinoma and subsequent therapy is required for all such cases. In such a situation, the extent of the disease should be assessed by a PET/CT scan if available, or a pelvic and abdominal CT or MRI scan, and chest imaging. The subsequent treatment plan is formulated based on the histologic and radiologic findings.

Although PORT for patients following inadvertent simple hysterectomy has been shown to be beneficial,<sup>116,117</sup> the outcome for such patients even after PORT remains very poor with 5-year recurrence-free survival of 49%,<sup>33</sup> and therefore CCRT is generally added. In a study from India, Sharma et al.<sup>116</sup> reported the results of 83 patients treated with PORT following either inadvertent simple hysterectomy (33 patients) or radical hysterectomy (50 patients). The 5-year recurrence-free survival was found to be significantly inferior in patients who underwent PORT after inadvertent simple hysterectomy (49% vs 72%, respectively;  $P=0.04$ ). PORT, therefore, does not compensate for lack of adequate surgery.

In centres where the expertise is available, some of these patients may be found suitable for repeat laparotomy with parametrectomy and pelvic lymphadenectomy. The procedure is challenging due to previous scarring, adhesions, and distortion of anatomy, but does have the potential for curative surgery as well as allow assessment of the need for adjuvant CCRT.<sup>118</sup>

### 5.3 | Post-treatment follow-up

In a systematic review of 17 retrospective studies that followed up women treated for cervical cancer, the median time to recurrence ranged from 7 to 36 months after primary treatment.<sup>119</sup> Therefore, closer clinical follow-up in the 2–3 years after treatment may be important. Routine follow-up visits are recommended every 3–4 months for the first 2–3 years, then 6-monthly until 5 years, and then annually for life. At each visit, history taking and clinical examination are carried out to detect treatment complications and psychosexual morbidity, as well as assess for recurrent disease.

Routine imaging is not indicated. Special circumstances, such as involved high pelvic lymph nodes, may justify interval imaging of the abdomen to assess for potentially curable progression of disease. In the systematic review, asymptomatic recurrent disease was detected using physical exam (29%–71%), chest X-ray (20%–47%), CT (0%–34%), and vaginal vault cytology (0%–17%). Frequent vaginal vault cytology does not significantly improve the detection of early disease recurrence. Patients should return to annual population-based screening after 5 years of disease-free survival.<sup>119</sup>

Women under the age of 50 years who have lost ovarian function should be considered for menopausal hormone therapy. As women age, the routine exam should include other age-indicated well-woman checks also to ensure quality of life, including assessment of thyroid and renal status.

### 5.4 | Recurrent disease

Recurrences may occur locally in the pelvic or para-aortic, the patient may develop distant metastases, or there may be a combination

thereof. The risk of both pelvic and distant failure increases in proportion to tumor volume.<sup>120,121</sup> Most recurrences are seen within 3 years and the prognosis is poor, as most patients die from progressive disease with uremia being the most common terminal event.<sup>119,122</sup> The treatment plan depends on the patient's performance status, site and extent of recurrence and/or metastases, and prior treatment received.<sup>123</sup>

If there is extensive local disease or distant metastatic disease, the patient is assigned to palliative therapy, with best supportive care and symptom control the recommended management. However, if the performance status is good and there is only limited metastatic disease, a trial of platinum doublet chemotherapy is justified, counseling the patient and her family with respect to the limited benefits with respect to response rate and progression-free survival.<sup>113</sup> Local recurrence that cannot be salvaged with surgery or radiotherapy is likely to have a very poor response to systemic chemotherapy.

#### 5.4.1 | Local recurrence

The pelvis is the most common site of recurrence and patients who have only locally recurrent disease after definitive therapy, whether surgery or radiotherapy, are in a more favorable situation as the disease is potentially curable. Good prognostic factors are the presence of an isolated central pelvic recurrence with no involvement of the pelvic sidewall, a long disease-free interval from previous therapy, and the largest diameter of the recurrent tumor is less than 3 cm.<sup>74,124</sup>

When the pelvic relapse follows primary surgery, it may be treated by either radical chemoradiation or pelvic exenteration. Confirmation of recurrence with a pathologic specimen obtained by biopsy is essential prior to proceeding with either therapy. Radical irradiation with or without concurrent chemotherapy may result in 5-year disease-free survival rates of 45%–74% with isolated pelvic failure after primary surgery.<sup>125,126</sup> The extent of recurrent disease and involvement of pelvic lymph nodes are prognostic factors for survival.<sup>127</sup>

Concurrent chemotherapy with either cisplatin and/or 5-fluorouracil may improve outcome.<sup>128</sup> IMRT is reported to be superior to conventional concurrent chemoradiation yielding better dose sparing of small bowel, rectum, and bladder than chemoradiation with significantly higher 5-year overall survival and progression-free survival rates (35.4% vs 21.4%; 26.1% and 15.1%, respectively).

Pelvic exenteration may be feasible in some patients in whom there is no evidence of intraperitoneal or extrapelvic spread, and there is a clear tumor-free space between the recurrent disease and the pelvic sidewall.<sup>71–75</sup> Owing to its high morbidity, it is reserved for those with expected curative potential and requires careful patient selection regarding the associated physical and psychological demands. A PET/CT scan is the most sensitive noninvasive test to determine any sites of distant disease, and should be performed prior to exenteration, if possible.<sup>129–136</sup> Patient assessment and counseling regarding the implications and ability to manage stoma and ostomy sites must also be addressed prior to surgery.<sup>137</sup> The overall survival is 10% but careful selection of patients has been reported to yield a 5-year survival with pelvic exenteration in the order of 30%–60%,<sup>71,72,74</sup> and an operative mortality of less than 10%.<sup>138</sup>

## 5.4.2 | Para-aortic nodal recurrence

The second most common site of recurrence is in the para-aortic lymph nodes. Where there is isolated para-aortic nodal recurrence, curative-intent radiation therapy or chemoradiation, can achieve long-term survival in approximately 30% of cases.<sup>139</sup> Better outcomes are seen in asymptomatic patients with low-volume recurrences occurring more than 24 months from initial treatment.

## 5.5 | Comprehensive palliative care

Symptom control is the essence of palliative care and plays a major role in maintaining dignity and quality of life. As the disease progresses, patients may present with a wide range of symptoms that need to be managed with individual attention. Common symptoms of advanced cervical cancer include: pain, ureteric obstruction causing renal failure, hemorrhage, malodorous vaginal discharge, lymphedema, and fistulae. Patients require support from the corresponding clinical services as well as psychosocial care and support for their families and caregivers. Typically a tiered approach to pain is practiced. Access to oral morphine is improving within LMICs and is an important aspect of palliative care. The availability of home care teams in many regions and involvement of nongovernmental organizations in this effort can help minimize the need to transport the patient to hospital and save costs too. In terminal cases, some patients may require the services of a hospice facility as well.

### 5.5.1 | Palliative radiotherapy

Common symptoms in patients with advanced incurable disease include vaginal bleeding, pelvic pain, malodorous discharge, and symptoms related to metastatic disease, which may be distressing to the patient. Short course radiotherapy is very effective in palliation of such symptoms. Although there is no standard dose fraction schedule, a dose of 20 Gy in five fractions over 1 week or 30 Gy in 10 fractions over 2 weeks is commonly practiced.<sup>140</sup> In patients with severe vaginal bleeding, a short course of EBRT may be tried and, if it fails, ICRT can be highly effective in controlling the intractable bleeding.<sup>141</sup> Control of bleeding is usually achieved after 12–48 hours of radiotherapy.

In patients with pain arising from enlarged para-aortic or supraclavicular nodes, skeletal metastases,<sup>142</sup> and symptoms associated with cerebral metastases, palliative radiotherapy should be given via larger fractions over shorter periods of time. Commonly used schedules include large single fractions, 20 Gy in five fractions, and 30 Gy in 10 fractions.

## 6 | SPECIAL SITUATIONS

### 6.1 | Cervical cancer during pregnancy

Adequate management of these patients requires a multidisciplinary team. The plan must be discussed with the patient and, preferably, her partner, as their wishes are to be respected.

Broadly, the management of cervical cancer in pregnancy follows the same principles as in the nonpregnant state. Before 16–20 weeks of pregnancy, patients are treated without delay. The mode of therapy can be either surgery or chemoradiation depending on the stage of the disease. Radiation often results in spontaneous abortion of the conceptus. From the late second trimester onward, surgery and chemotherapy can be used in selected cases while preserving the pregnancy.<sup>143</sup> When the diagnosis is made after 20 weeks, delaying definitive treatment is a valid option for Stages IA2 and IB1 and 1B2, which has not been shown to have any negative impact on the prognosis compared with nonpregnant controls.<sup>144–146</sup> Timing of delivery requires a balance between maternal and fetal health interests. When delivered at a tertiary center with appropriate neonatal care, delivery by classical cesarean and radical hysterectomy at the same time is undertaken not later than 34 weeks of pregnancy.

For more advanced disease, the impact of treatment delay on survival is not known. Neoadjuvant chemotherapy may be administered to prevent disease progression in women with locally advanced cervical cancer when a treatment delay is planned.<sup>147,148</sup>

## AUTHOR CONTRIBUTIONS

All authors contributed to the manuscript at all stages including design, planning, data abstraction, and manuscript writing.

## ACKNOWLEDGMENTS

This chapter reworks and updates the information published in the FIGO Cancer Report 2015 (Bermudez A, Bhatla N, Leung E. Cancer of the cervix uteri. *Int J Gynecol Obstet.* 2015;131(Suppl.2):S88–95), with approval granted by the original authors. Dr Jayashree Natarajan's help in reviewing the literature is gratefully acknowledged.

## CONFLICTS OF INTEREST

NB has received research funding through her Institute from MSD, GlaxoSmithKline, and Digene/Qiagen Inc. DA has received honoraria from AstraZeneca KK, Chugai Pharmaceutical Co. Ltd, Ono Pharmaceutical Co. Ltd, and Takeda Pharmaceutical Co. Ltd. DNS and RS have no conflicts of interest to declare.

## REFERENCES

1. Ferlay J, Soerjomataram I, Ervik M, et al. *GLOBOCAN 2012 v1.0, Cancer Incidence and Mortality Worldwide: IARC CancerBase No. 11* [Internet]. Lyon, France: International Agency for Research on Cancer; 2013.
2. Bosch FX, Lorincz A, Muñoz N, et al. The causal relation between human papillomavirus and cervical cancer. *J Clin Pathol.* 2002;55:244–265.
3. IARC Working Group. *Human Papillomaviruses: IARC Monographs on the Evaluation of Carcinogenic Risks to Humans*. Lyon: International Agency for Research on Cancer; 2007:90.

4. Bruni L, Diaz M, Castellsague X, et al. Cervical human papillomavirus prevalence in 5 continents: Meta-analysis of 1 million women with normal cytological findings. *J Infect Dis*. 2010;202:1789–1799.
5. World Health Organization. Human papillomavirus vaccines: WHO position paper, May 2017. *Wkly Epidemiol Rec*. 2017;92:241–268.
6. Saccucci M, Franco EL, Ding L, et al. Non-vaccine-type human papillomavirus prevalence after vaccine introduction: No evidence for type replacement but evidence for cross-protection. *Sex Transm Dis*. 2018;45:260–265.
7. Drolet M, Bénard É, Boily MC, et al. Population-level impact and herd effects following human papillomavirus vaccination programmes: A systematic review and meta-analysis. *Lancet Infect Dis*. 2015;15:565–580.
8. Garland SM, Kjaer SK, Muñoz N, et al. Impact and effectiveness of the quadrivalent human papillomavirus vaccine: A systematic review of 10 years of real-world experience. *Clin Infect Dis*. 2016;63:519–527.
9. Sankaranarayanan R, Joshi S, Muwonge R, et al. Can a single dose of human papillomavirus (HPV) vaccine prevent cervical cancer? Early findings from an Indian study *Vaccine*. 2018;36:4783–4791.
10. Kreimer AR, Herrero R, Sampson JN, et al. Evidence for single-dose protection by the bivalent HPV vaccine-Review of the Costa Rica HPV vaccine trial and future research studies. *Vaccine*. 2018;36:4774–4782.
11. Sankaranarayanan R. Screening for cancer in low- and middle-income countries. *Ann Glob Health*. 2014;80:412–417.
12. Sankaranarayanan R, Nene BM, Shastri SS, et al. HPV screening for cervical cancer in rural India. *N Engl J Med*. 2009;360:1385–1394.
13. Ronco G, Giorgi-Rossi P, Carozzi F, et al. Efficacy of human papillomavirus testing for the detection of invasive cervical cancers and cervical intraepithelial neoplasia: A randomised controlled trial. *Lancet Oncol*. 2010;11:249–257.
14. Shiferaw N, Salvador-Davila G, Kassahun K, et al. The single-visit approach as a cervical cancer prevention strategy among women with HIV in Ethiopia: Successes and lessons learned. *Glob Health Sci Pract*. 2016;4:87–98.
15. Msyamboza KP, Phiri T, Sichali W, et al. Cervical cancer screening uptake and challenges in Malawi from 2011 to 2015: Retrospective cohort study. *BMC Public Health*. 2016;16:806.
16. Parham GP, Mwanahamuntu MH, Kapambwe S, et al. Population-level scale-up of cervical cancer prevention services in a low-resource setting: Development, implementation, and evaluation of the cervical cancer prevention program in Zambia. *PLoS ONE*. 2015;10:e0122169.
17. Bhatla N, Berek J, Cuello M, et al. New revised FIGO staging of cervical cancer (2018). Abstract S020.2. Presented at the FIGO XXII World Congress of Gynecology and Obstetrics. Rio de Janeiro, Brazil, October 14–19, 2018. *Int J Gynecol Obstet* 2018;143(Suppl.3):DOI: 10.1002/ijgo.12584.
18. Roman LD, Felix JC, Muderspach LI, Agahjanian A, Qian D, Morrow CP. Risk of residual invasive disease in women with microinvasive squamous cancer in a conization specimen. *Obstet Gynecol*. 1997;90:759–764.
19. Hricak H, Gatsonis C, Chi DS, et al. Role of imaging in pretreatment evaluation of early invasive cervical cancer: Results of the intergroup study American College of Radiology Imaging Network 6651-Gynecologic Oncology Group 183. *J Clin Oncol*. 2005;23:9329–9337.
20. Bipat S, Glas AS, van der Velden J, Zwinderman AH, Bossuyt PM, Stoker J. Computed tomography and magnetic resonance imaging in staging of uterine cervical carcinoma: A systematic review. *Gynecol Oncol*. 2003;91:59–66.
21. Hricak H, Yu KK. Radiology in invasive cervical cancer. *Am J Roentgenol*. 1996;167:1101–1108.
22. Subak LL, Hricak H, Powell CB, Azizi L, Stern JL. Cervical carcinoma: Computed tomography and magnetic resonance imaging for preoperative staging. *Obstet Gynecol*. 1995;86:43–50.
23. Kodama J, Mizutani Y, Hongo A, Yoshinouchi M, Kudo T, Okuda H. Optimal surgery and diagnostic approach of stage IA2 squamous cell carcinoma of the cervix. *Eur J Obstet Gynecol Reprod Biol*. 2002;101:192–195.
24. Grigsby PW, Siegel BA, Dehdashti F. Lymph node staging by positron emission tomography in patients with carcinoma of the cervix. *J Clin Oncol*. 2001;19:3745–3749.
25. Fischerova D, Cibula D, Stenhova H, et al. Transrectal ultrasound and magnetic resonance imaging in staging of early cervical cancer. *Int J Gynecol Cancer*. 2008;18:766–772.
26. Yang WT, Lam WW, Yu MY, Cheung TH, Metreweli C. Comparison of dynamic helical CT and dynamic MR imaging in the evaluation of pelvic lymph nodes in cervical carcinoma. *Am J Roentgenol*. 2000;175:759–766.
27. Havrilesky LJ, Kulasingam SL, Matchar DB, Myers ER. FDG-PET for management of cervical and ovarian cancer. *Gynecol Oncol*. 2005;97:183–191.
28. Rose PG, Adler LP, Rodriguez M, Faulhaber PF, Abdul-Karim FW, Miraldi F. Positron emission tomography for evaluating para-aortic nodal metastasis in locally advanced cervical cancer before surgical staging: A surgicopathologic study. *J Clin Oncol*. 1999;17:41–45.
29. Sakurai H, Suzuki Y, Nonaka T, et al. FDG-PET in the detection of recurrence of uterine cervical carcinoma following radiation therapy-tumor volume and FDG uptake value. *Gynecol Oncol*. 2006;100:601–607.
30. Yen T-C, Ng K-K, Ma S-Y, et al. Value of dual-phase 2-fluoro-2-deoxy-d-glucose positron emission tomography in cervical cancer. *J Clin Oncol*. 2003;21:3651–3658.
31. Hertel H, Köhler C, Elhawary T, Michels W, Possover M, Schneider A. Laparoscopic staging compared with imaging techniques in the staging of advanced cervical cancer. *Gynecol Oncol*. 2002;87:46–51.
32. Ramirez PT, Jhingran A, Macapinlac HA, et al. Laparoscopic extra-peritoneal para-aortic lymphadenectomy in locally advanced cervical cancer: A prospective correlation of surgical findings with positron emission tomography/computed tomography findings. *Cancer*. 2011;117:1928–1934.
33. Marnitz S, Köhler C, Roth C, Füller J, Hinkelbein W, Schneider A. Is there a benefit of pretreatment laparoscopic transperitoneal surgical staging in patients with advanced cervical cancer? *Gynecol Oncol*. 2005;99:536–544.
34. Gold MA, Tian C, Whitney CW, Rose PG, Lanciano R. Surgical versus radiographic determination of para-aortic lymph node metastases before chemoradiation for locally advanced cervical carcinoma: A Gynecologic Oncology Group Study. *Cancer*. 2008;112:1954–1963.
35. Smits RM, Zusterzeel PLM, Bekkers RLM. Pretreatment retroperitoneal para-aortic lymph node staging in advanced cervical cancer: A review. *Int J Gynecol Cancer*. 2014;24–6:973–983.
36. Heller PB, Maletano JH, Bundy BN, Barnhill DR, Okagaki T. Clinical-pathologic study of stage IIB, III, and IVA carcinoma of the cervix: Extended diagnostic evaluation for paraaortic node metastasis—a Gynecologic Oncology Group study. *Gynecol Oncol*. 1990;38:425–430.
37. Delgado G, Bundy B. Prospective surgico pathological study of disease free interval in patients with Stage IB squamous cell carcinoma of cervix. A gynecological oncology Group study. *Gynecol Oncol*. 1990;38:352–357.
38. Edge SB, Byrd DR, Compton CC, Faiz AG, Greene FL, Trotti A, eds. Gynecologic Sites. In: *AJCC Cancer Staging Manual*. 7th edn. New York; London: Springer; 2010:395–402.
39. Kurman RJ, Carcangiu ML, Herrington CS, Young RH. *WHO Classification of Tumours of Female Reproductive Organs*, 4th edn. Lyon: IARC; 2014.
40. Lee SW, Kim YM, Son WS, et al. The efficacy of conservative management after conization in patients with stage IA1 microinvasive cervical carcinoma. *Acta Obstet Gynecol Scand*. 2009;88:209–215.



41. Sevin BU, Nadji M, Averette HE, et al. Microinvasive carcinoma of the cervix. *Cancer*. 1992;70:2121–2128.
42. Elliott P, Coppleson M, Russell P, et al. Early invasive (FIGO stage IA) carcinoma of the cervix: A clinico-pathologic study of 476 cases. *Int J Gynecol Cancer*. 2000;10:42–52.
43. Webb JC, Key CR, Qualls CR, Smith HO. Population-based study of microinvasive adenocarcinoma of the uterine cervix. *Obstet Gynecol*. 2001;97(5 Pt 1):701–706.
44. van Meurs H, Visser O, Buist MR, et al. Frequency of pelvic lymph node metastases and parametrial involvement in stage IA2 cervical cancer: A population-based study and literature review. *Int J Gynecol Cancer*. 2009;19:21–26.
45. Costa S, Marra E, Martinelli GN, et al. Outcome of conservatively treated microinvasive squamous cell carcinoma of the uterine cervix during a 10-year follow-up. *Int J Gynecol Cancer*. 2009;19:33–38.
46. Bouchard-Fortier G, Reade CJ, Covens A. Non-radical surgery for small early-stage cervical cancer. Is it time? *Gynecol Oncol*. 2014;132:624–627.
47. Kato T, Takashima A, Kasamatsu T, et al.; Gynecologic Oncology Study Group of the Japan Clinical Oncology Group. Clinical tumor diameter and prognosis of patients with FIGO stage IB1 cervical cancer (JCOG0806-A). *Gynecol Oncol*. 2015;137:34–39.
48. Coutant C, Cordier AG, Guillo E, Ballester M, Rouzier R, Darai E. Clues pointing to simple hysterectomy to treat early-stage cervical cancer. *Oncol Rep*. 2009;22:927–934.
49. Frumovitz M, Sun CC, Schmeler KM, et al. Parametrial involvement in radical hysterectomy specimens for women with early-stage cervical cancer. *Obstet Gynecol*. 2009;114:93–99.
50. Shepherd JH, Spencer C, Herod J, Ind TE. Radical vaginal trachelectomy as a fertility-sparing procedure in women with early-stage cervical cancer-cumulative pregnancy rate in a series of 123 women. *BJOG*. 2006;113:719–724.
51. Quinn MA, Benedet JL, Odicino F, et al. Carcinoma of the cervix uteri. FIGO 26th Annual Report on the Results of Treatment in Gynecological Cancer. *Int J Gynecol Obstet*. 2006;95(Suppl.1):S43–S103.
52. Landoni F, Maneo A, Colombo A, et al. Randomised study of radical surgery versus radiotherapy for stage Ib-IIa cervical cancer. *Lancet*. 1997;350:535–540.
53. Eifel PJ, Morris M, Wharton JT, Oswald MJ. The influence of tumor size and morphology on the outcome of patients with FIGO stage IB squamous cell carcinoma of the uterine cervix. *Int J Radiat Oncol Biol Phys*. 1994;29:9–16.
54. Landoni F, Maneo A, Cormio G, et al. Class II versus class III radical hysterectomy in stage IB-IIA cervical cancer: A prospective randomized study. *Gynecol Oncol*. 2001;80:3–12.
55. Fujii S, Takakura K, Matsumura N, et al. Anatomic identification and functional outcomes of the nerve sparing Okabayashi radical hysterectomy. *Gynecol Oncol*. 2007;107:4–13.
56. Roh JW, Lee DO, Suh DH, et al. Efficacy and oncologic safety of nerve-sparing radical hysterectomy for cervical cancer: A randomized controlled trial. *J Gynecol Oncol*. 2015;26:90–99.
57. Abu-Rustum NR, Sonoda Y, Black D, et al. Fertility-sparing radical abdominal trachelectomy for cervical carcinoma: Technique and review of the literature. *Gynecol Oncol*. 2006;103:807–813.
58. Martínez-Palones JM, Gil-Moreno A, Pérez-Benavente MA, Roca I, Xercavins J. Intraoperative sentinel node identification in early stage cervical cancer using a combination of radiolabeled albumin injection and isosulfan blue dye injection. *Gynecol Oncol*. 2004;92:845–850.
59. van de Lande J, Torrenga B, Rajmakers PG, et al. Sentinel lymph node detection in early stage uterine cervix carcinoma: A systematic review. *Gynecol Oncol*. 2007;106:604–613.
60. Gortzak-Uzan L, Jimenez W, Nofech-Mozes S, et al. Sentinel lymph node biopsy vs. pelvic lymphadenectomy in early stage cervical cancer: Is it time to change the gold standard? *Gynecol Oncol*. 2010;116:28–32.
61. Levenback C, Coleman RL, Burke TW, et al. Lymphatic mapping and sentinel node identification in patients with cervix cancer undergoing radical hysterectomy and pelvic lymphadenectomy. *J Clin Oncol*. 2002;20:688–693.
62. Hauspy J, Beiner M, Harley I, Ehrlich L, Rasty G, Covens A. Sentinel lymph nodes in early stage cervical cancer. *Gynecol Oncol*. 2007;105:285–290.
63. Ramirez PT, Frumovitz M, Parejab R, Lopezc A, Vieirad MA, Ribeiro RA. Phase III randomized trial of laparoscopic or robotic versus abdominal radical hysterectomy in patients with early stage cervical cancer: LACC Trial. Abstract presented at the 49th Annual Meeting of the Society of Gynecologic Oncology, March 24–27, 2018. New Orleans, LA, USA.
64. Rotman M, Sedlis A, Piedmonte MR, et al. A phase III randomized trial of postoperative pelvic irradiation in Stage IB cervical carcinoma with poor prognostic features: Follow-up of a gynecologic oncology group study. *Int J Radiat Oncol Biol Phys*. 2006;65:169–176.
65. Sedlis A, Bundy BN, Rotman MZ, Lentz SS, Mudderspach LI, Zaino RJ. A randomized trial of pelvic radiation therapy versus no further therapy in selected patients with stage IB carcinoma of the cervix after radical hysterectomy and pelvic lymphadenectomy: A Gynecologic Oncology Group Study. *Gynecol Oncol*. 1999;73:177–183.
66. Rose PG, Ali S, Watkins E, et al.; Gynecologic Oncology Group. Long-term follow-up of a randomized trial comparing concurrent single agent cisplatin, cisplatin-based combination chemotherapy, or hydroxyurea during pelvic irradiation for locally advanced cervical cancer: A Gynecologic Oncology Group Study. *J Clin Oncol*. 2007;25:2804–2810.
67. Peters WA III, Liu PY, Barrett RJ II, et al. Concurrent chemotherapy and pelvic radiation therapy compared with pelvic radiation therapy alone as adjuvant therapy after radical surgery in high-risk early-stage cancer of the cervix. *J Clin Oncol*. 2000;18:1606–1613.
68. Neoadjuvant Chemotherapy for Locally Advanced Cervical Cancer Meta-analysis Collaboration. Neoadjuvant chemotherapy for locally advanced cervical cancer: A systematic review and meta-analysis of individual patient data from 21 randomised trials. *Eur J Cancer*. 2003;39:2470–2486.
69. Mossa B, Mossa S, Corosu L, Marziani R. Follow-up in a long-term randomized trial with neoadjuvant chemotherapy for squamous cell cervical carcinoma. *Eur J Gynaecol Oncol*. 2010;31:497–503.
70. Dastidar GA, Gupta P, Basu B, Shah JK, Seal SL. Is neo-adjuvant chemotherapy a better option for management of cervical cancer patients of rural India? *Indian J Cancer*. 2016;53:1:56–59.
71. Shingleton HM, Soong SJ, Gelder MS, Hatch KD, Baker VV, Austin JM Jr. Clinical and histopathologic factors predicting recurrence and survival after pelvic exenteration for cancer of the cervix. *Obstet Gynecol*. 1989;73:1027–1034.
72. Rutledge FN, Smith JP, Wharton JT, O'Quinn AG. Pelvic exenteration: Analysis of 296 patients. *Am J Obstet Gynecol*. 1977;129:881–892.
73. Morley GW, Hopkins MP, Lindenauer SM, Roberts JA. Pelvic exenteration, University of Michigan: 100 patients at 5 years. *Obstet Gynecol*. 1989;74:934–943.
74. Estape R, Angioli R. Surgical management of advanced and recurrent cervical cancer. *Semin Surg Oncol*. 1999;16:236–241.
75. Benn T, Brooks RA, Zhang Q, et al. Pelvic exenteration in gynecologic oncology: A single institution study over 20 years. *Gynecol Oncol*. 2011;122:14–18.
76. Sankaranarayanan R. Overview of cervical cancer in the developing world. FIGO 26th annual report on the results of treatment in gynecological cancer. *Int J Gynecol Obstet*. 2006;95:S205–S210.
77. Dutta S, Nguyen NP, Vock J, et al. Image-guided radiotherapy and brachytherapy for cervical cancer. *Front Oncol*. 2015;5:64.
78. Harkenrider MM, Alite F, Silva SR, Small W Jr. Image-based brachytherapy for the treatment of cervical cancer. *Int J Radiat Oncol Biol Phys*. 2015;92:921–934.



79. Grigsby PW, Perez CA. Radiotherapy alone for medically inoperable carcinoma of the cervix: Stage IA and carcinoma in situ. *Int J Radiat Oncol Biol Phys*. 1991;21:375.
80. Landoni F, Colombo A, Milani R, Placa F, Zanagnolo V, Mangioni C. Randomized study between radical surgery and radiotherapy for the treatment of stage IB-IIA cervical cancer: 20-year update. *J Gynecol Oncol*. 2017;28:e34.
81. Fuller AF Jr, Elliott N, Kosloff C, et al. Determinants of increased risk for recurrence in patients undergoing radical hysterectomy for stage IB and IIA carcinoma of the cervix. *Gynecol Oncol*. 1989;33:34–39.
82. Póka R, Molnár S, Daragó P, et al. Intention-to-treat analysis of radical trachelectomy for early-stage cervical cancer with special reference to oncologic failures. *Int J Gynecol Cancer*. 2017;27:1438–1445.
83. Bentivegna E, Maulard A, Pautier P, Chargari C, Gouy S, Morice P. Fertility results and pregnancy outcomes after conservative treatment of cervical cancer: A systematic review of the literature. *Fertil Steril*. 2016;106:1195–1211.
84. Hauerberg L, Høgdall C, Loft A, et al. Vaginal radical trachelectomy for early stage cervical cancer. Results of the Danish National Single Center Strategy. *Gynecol Oncol*. 2015;138:304–310.
85. Park JY, Joo WD, Chang SJ, et al. Long-term outcomes after fertility-sparing laparoscopic radical trachelectomy in young women with early-stage cervical cancer: An Asan Gynecologic Cancer Group (AGCG) study. *J Surg Oncol*. 2014;110:252–257.
86. Plante M, Gregoire J, Renaud MC, Roy M. The vaginal radical trachelectomy: An update of a series of 125 cases and 106 pregnancies. *Gynecol Oncol*. 2011;121:290–297.
87. Plante M, Renaud MC, Sebastianelli A, Gregoire J. Simple vaginal trachelectomy: A valuable fertility-preserving option in early-stage cervical cancer. *Int J Gynecol Cancer*. 2017;27:1021–1027.
88. Ramirez PT, Pareja R, Rendón GJ, Millan C, Frumovitz M, Schmeler KM. Management of low-risk early-stage cervical cancer: Should conization, simple trachelectomy, or simple hysterectomy replace radical surgery as the new standard of care? *Gynecol Oncol*. 2014;132:254–259.
89. Schmeler KM, Frumovitz M, Ramirez PT. Conservative management of early stage cervical cancer: Is there a role for less radical surgery? *Gynecol Oncol*. 2011;120:321–325.
90. Zhang Q, Li W, Kanis MJ, et al. Oncologic and obstetrical outcomes with fertility-sparing treatment of cervical cancer: A systematic review and meta-analysis. *Oncotarget*. 2017;8:46580–46592.
91. Gemer O, Lavie O, Gdalevich M, et al. Evaluation of clinical and pathologic risk factors may reduce the rate of multimodality treatment of early cervical cancer. *Am J Clin Oncol*. 2016;39:37–42.
92. Small W, Mell LK, Anderson P, et al. Consensus guidelines for delineation of clinical target volume for intensity-modulated pelvic radiotherapy in postoperative treatment of endometrial and cervical cancer. *Int J Radiat Oncol Biol Phys*. 2008;71:428–434.
93. Klopp A, Yeung A, Deshmukh S, et al. A phase III randomized trial comparing patient-reported toxicity and quality of life (QOL) during pelvic intensity modulated radiation therapy as compared to conventional radiation therapy. *Int J Radiat Oncol Biol Phys*. 2016;96:S3.
94. Small W Jr, Beriwal S, Demanes DJ, et al. American Brachytherapy Society consensus guidelines for adjuvant vaginal cuff brachytherapy after hysterectomy. *Brachytherapy*. 2012;11:58–67.
95. Yeo RM, Chia YN, Namuduri RP, et al. Tailoring adjuvant radiotherapy for stage IB-IIA node negative cervical carcinoma after radical hysterectomy and pelvic lymph node dissection using the GOG score. *Gynecol Oncol*. 2011;123:225–229.
96. Minig L, Patrono MG, Romero N, et al. Different strategies of treatment for uterine cervical carcinoma stage IB2-IIB. *World J Clin Oncol*. 2014;5:86–92.
97. Whitney CW, Sause W, Bundy BN, et al. Randomized comparison of fluorouracil plus cisplatin versus hydroxyurea as an adjunct to radiation therapy in stage IIB-IVA carcinoma of the cervix with negative para-aortic lymph nodes: A Gynecologic Oncology Group and Southwest Oncology Group study. *J Clin Oncol*. 1999;17:1339–1348.
98. Morris M, Eifel PJ, Lu J, et al. Pelvic radiation with concurrent chemotherapy compared with pelvic and para-aortic radiation for high-risk cervical cancer. *N Engl J Med*. 1999;340:1137–1143.
99. Rose PG, Bundy BN, Watkins EB, et al. Concurrent cisplatin-based radiotherapy and chemotherapy for locally advanced cervical cancer. *N Engl J Med*. 1999;340:1144–1153.
100. Keys HM, Bundy BN, Stehman FB, et al. Cisplatin, radiation, and adjuvant hysterectomy compared with radiation and adjuvant hysterectomy for bulky stage IB cervical carcinoma. *N Engl J Med*. 1999;340:1154–1161.
101. National Cancer Institute. Concurrent chemoradiation for cervical cancer. Clinical announcement. NCI; 1999.
102. Vale C, Tierney JF, Stewart LA, et al. Reducing uncertainties about the effects of chemoradiotherapy for cervical cancer: A systematic review and meta-analysis of individual patient data from 18 randomized trials. *J Clin Oncol*. 2008;26:5802–5812.
103. Kim YS, Shin SS, Nam JH, et al. Prospective randomized comparison of monthly fluorouracil and cisplatin versus weekly cisplatin concurrent with pelvic radiotherapy and high-dose rate brachytherapy for locally advanced cervical cancer. *Gynecol Oncol*. 2008;108:195–200.
104. Lanciano R, Calkins A, Bundy BN, et al. Randomized comparison of weekly cisplatin or protracted venous infusion of fluorouracil in combination with pelvic radiation in advanced cervix cancer: A gynecologic oncology group study. *J Clin Oncol*. 2005;23:8289–8295.
105. Varia MA, Bundy BN, Deppe G, et al. Cervical carcinoma metastatic to para-aortic nodes: Extended field radiation therapy with concomitant 5-fluorouracil and cisplatin chemotherapy: A Gynecologic Oncology Group study. *Int J Radiat Oncol Biol Phys*. 1998;42:1015–1023.
106. Grigsby PW, Lu JD, Mutch DG, Kim RY, Eifel PJ. Twice-daily fractionation of external irradiation with brachytherapy and chemotherapy in carcinoma of the cervix with positive para-aortic lymph nodes: Phase II study of the Radiation Therapy Oncology Group 92-10. *Int J Radiat Oncol Biol Phys*. 1998;41:817–822.
107. National Cancer Institute. Clinical Trials Home Page. <http://www.cancer.gov/clinicaltrials>. Accessed February 8, 2018.
108. Sharma DN, Rath GK, Gandhi AK, et al. Low-dose-rate versus high-dose-rate versus pulsed-dose-rate intracavitary brachytherapy in cervical carcinoma: A mono-institutional comparative study. *Int J Radiat Oncol Biol Phys*. 2015;93(3 Suppl):e278.
109. Sharma DN, Rath GK, Thulkar S, et al. Use of transrectal ultrasound for high dose rate interstitial brachytherapy for patients of carcinoma of uterine cervix. *J Gynecol Oncol*. 2010;21:12–17.
110. Perez CA, Grigsby PW, Castro-Vita H, Lockett MA. Carcinoma of the uterine cervix. I. Impact of prolongation of overall treatment time and timing of brachytherapy on outcome of radiation therapy. *Int J Radiat Oncol Biol Phys*. 1995;32:1275–1288.
111. Lanciano RM, Pajak TF, Martz K, Hanks GE. The influence of treatment time on outcome for squamous cell cancer of the uterine cervix treated with radiation: A patterns-of-care study. *Int J Radiat Oncol Biol Phys*. 1993;25:391–397.
112. Lim KC, Howells RE, Evans AS. The role of clinical follow up in early stage cervical cancer in South Wales. *BJOG*. 2004;111:1444–1448.
113. Moore DH, Blessing JA, McQuellon RP, et al. Phase III study of cisplatin with or without paclitaxel in stage IVB, recurrent, or persistent squamous cell carcinoma of the cervix: A gynecologic oncology group study. *J Clin Oncol*. 2004;22:3113–3119.
114. Monk BJ, Sill MW, McMeekin DS, et al. Phase III trial of four cisplatin-containing doublet combinations in stage IVB, recurrent, or persistent cervical carcinoma: A Gynecologic Oncology Group study. *J Clin Oncol*. 2009;27:4649–4655.

115. Tewari KS, Sill MW, Penson RT, et al. Bevacizumab for advanced cervical cancer: Final overall survival and adverse event analysis of a randomised, controlled, open-label, phase 3 trial (Gynecologic Oncology Group 240). *Lancet*. 2017;390:1654–1663.
116. Sharma DN, Rath GK, Bhatla N, et al. Postoperative radiotherapy following inadvertent simple hysterectomy versus radical hysterectomy for cervical carcinoma. *Asian Pac J Cancer Prev*. 2011;12:1537–1541.
117. Saibishkumar EP, Patel FD, Ghoshal S, et al. Results of salvage radiotherapy after inadequate surgery in invasive cervical carcinoma patients: A retrospective analysis. *Int J Radiat Oncol Biol Phys*. 2005;63:828–833.
118. Kinney WK, Egorshin EV, Ballard DJ, Podratz KC. Long-term survival and sequelae after surgical management of invasive cervical carcinoma diagnosed at the time of simple hysterectomy. *Gynecol Oncol*. 1992;44:24–27.
119. Elit L, Fyles AW, Devries MC, Oliver TK, Fung-Kee-Fung M. Follow-up for women after treatment for cervical cancer: A systematic review. *Gynecol Oncol*. 2009;114:528–535.
120. Eifel PJ, Jhingran A, Brown J, Levenback C, Thames H. Time course and outcome of central recurrence after radiation therapy for carcinoma of the cervix. *Int J Gynecol Cancer*. 2006;16:1106–1111.
121. Fagundes H, Perez CA, Grigsby PW, Lockett MA. Distant metastases after irradiation alone in carcinoma of the uterine cervix. *Int J Radiat Oncol Biol Phys*. 1992;24:197–204.
122. van Nagell JR, Rayburn W, Donaldson ES, et al. Therapeutic implications of patterns of recurrence in cancer of the uterine cervix. *Cancer*. 1979;44:2354–2361.
123. Eralp Y, Saip P, Sakar B, et al. Prognostic factors and survival in patients with metastatic or recurrent carcinoma of the uterine cervix. *Int J Gynecol Cancer*. 2003;13:497–504.
124. Friedlander M, Grogan M; U.S. Preventative Services Task Force. Guidelines for the treatment of recurrent and metastatic cervical cancer. *Oncologist*. 2002;7:342–347.
125. Grigsby PW. Radiotherapy for pelvic recurrence after radical hysterectomy for cervical cancer. *Radiat Med*. 2005;23:327–330.
126. Haasbeek CJ, Uitterhoeve AL, van der Velden J, González DG, Stalpers LJ. Long-term results of salvage radiotherapy for the treatment of recurrent cervical carcinoma after prior surgery. *Radiother Oncol*. 2008;89:197–204.
127. Piura B, Rabinovich A, Friger M. Recurrent cervical carcinoma after radical hysterectomy and pelvic lymph node dissection: A study of 32 cases. *Eur J Gynaecol Oncol*. 2008;29:31–36.
128. Lee YS, Kim YS, Kim JH, et al. Feasibility and outcome of concurrent chemoradiotherapy for recurrent cervical carcinoma after initial surgery. *Tumori*. 2010;96:553–559.
129. Sun SS, Chen TC, Yen RF, Shen YY, Changlai SP, Kao A. Value of whole body 18F-fluoro-2-deoxyglucose positron emission tomography in the evaluation of recurrent cervical cancer. *Anticancer Res*. 2001;21(4B):2957–2961.
130. Husain A, Akhurst T, Larson S, Alektiar K, Barakat RR, Chi DS. A prospective study of the accuracy of 18Fluorodeoxyglucose positron emission tomography (18FDG PET) in identifying sites of metastasis prior to pelvic exenteration. *Gynecol Oncol*. 2007;106:177–180.
131. Unger JB, Ivy JJ, Connor P, et al. Detection of recurrent cervical cancer by whole-body FDG PET scan in asymptomatic and symptomatic women. *Gynecol Oncol*. 2004;94:212–216.
132. Havrilesky LJ, Wong TZ, Secord AA, Berchuck A, Clarke-Pearson DL, Jones EL. The role of PET scanning in the detection of recurrent cervical cancer. *Gynecol Oncol*. 2003;90:186–190.
133. Chung HH, Jo H, Kang WJ, et al. Clinical impact of integrated PET/CT on the management of suspected cervical cancer recurrence. *Gynecol Oncol*. 2007;104:529–534.
134. Pallardy A, Bodet-Milin C, Oudoux A, et al. Clinical and survival impact of FDG PET in patients with suspicion of recurrent cervical carcinoma. *Eur J Nucl Med Mol Imaging*. 2010;37:1270–1278.
135. Mittra E, El-Maghraby T, Rodriguez CA, et al. Efficacy of 18F-FDG PET/CT in the evaluation of patients with recurrent cervical carcinoma. *Eur J Nucl Med Mol Imaging*. 2009;36:1952–1959.
136. Kitajima K, Murakami K, Yamasaki E, Domeki Y, Kaji Y, Sugimura K. Performance of FDG-PET/CT for diagnosis of recurrent uterine cervical cancer. *Eur Radiol*. 2008;18:2040–2047.
137. Ruth-Sahd LA, Zulkosky KD. Cervical cancer: Caring for patients undergoing total pelvic exenteration. *Crit Care Nurse*. 1999;19:46–57.
138. Höckel M, Dornhöfer N. Pelvic exenteration for gynaecological tumours: Achievements and unanswered questions. *Lancet Oncol*. 2006;7:837–847.
139. Niibe Y, Kenjo M, Kazumoto T, et al. Multi-institutional study of radiation therapy for isolated para-aortic lymph node recurrence in uterine cervical carcinoma: 84 subjects of a population of more than 5,000. *Int J Radiat Oncol Biol Phys*. 2006;66:1366–1369.
140. Sharma DN, Gandhi AK, Adhikari N. Definitive radiation therapy of locally advanced cervical cancer initially treated with palliative hypofractionated radiation therapy. *Int J Radiat Oncol Biol Phys*. 2016;96(2 Suppl):e306.
141. Biswal BM, Lal P, Rath GK, Mohanti BK. Hemostatic radiotherapy in carcinoma of the uterine cervix. *Int J Gynaecol Obstet*. 1995;50:281–285.
142. Chow E, Zeng L, Salvo N, Dennis K, Tsao M, Lutz S. Update on the systematic review of palliative radiotherapy trials for bone metastases. *Clin Oncol (R Coll Radiol)*. 2012;24:112–124.
143. Amant F, Brepoels L, Halaska MJ, Gziri MM, Calsteren KV. Gynaecologic cancer complicating pregnancy: An overview. *Best Pract Res Clin Obstet Gynaecol*. 2010;24:61–79.
144. Duggan B, Muderspach LI, Roman LD, Curtin JP, d'Ablaing G 3rd, Morrow CP. Cervical cancer in pregnancy: Reporting on planned delay in therapy. *Obstet Gynecol*. 1993;82(4 Pt 1):598–602.
145. Nevin J, Soeters R, Dehaeck K, Bloch B, Van Wyk L. Advanced cervical carcinoma associated with pregnancy. *Int J Gynecol Cancer*. 1993;3:57–63.
146. Hunter MI, Tewari K, Monk BJ. Cervical neoplasia in pregnancy. Part 2: Current treatment of invasive disease. *Am J Obstet Gynecol*. 2008;199:10–18.
147. Tewari K, Cappuccini F, Gambino A, Kohler MF, Pecorelli S, DiSaia PJ. Neoadjuvant chemotherapy in the treatment of locally advanced cervical carcinoma in pregnancy: A report of two cases and review of issues specific to the management of cervical carcinoma in pregnancy including planned delay of therapy. *Cancer*. 1998;82:1529–1534.
148. Boyd A, Cowie V, Gourley C. The use of cisplatin to treat advanced-stage cervical cancer during pregnancy allows fetal development and prevents cancer progression: Report of a case and review of the literature. *Int J Gynecol Cancer*. 2009;19:273–276.